

---

## Research Article

---

Open Access, Volume 3

# Case reports of functional adaptation of free fibula grafts in mandibula's, treated with extra short implants

Rolf Ewers<sup>1\*</sup>; Mauro Marincola<sup>2</sup>; Paolo Perpetuini<sup>3</sup>; Estevam A. Bonfante<sup>4</sup>

<sup>1</sup>Former Head of the University Hospital for Cranio-Maxillofacial-and Oral Surgery, Waehringer Guertel 18-20. 1090 Vienna, Austria and Head of the CMF Institute Vienna, Roosevelt Platz 12 1090 Vienna, Austria.

<sup>2</sup>Implant Dentistry Center University of Cartagena, Cartagena, Colombia.

<sup>3</sup>Dental Technician, Laboratorio Odontotecnico, Via Dante Alighieri 19, I-04012 Cisterna di Latina, Italy.

<sup>4</sup>Department of Prosthodontics and Periodontology, University of Sao Paulo - Bauru School of Dentistry, Bauru, SP, Brazil.

### \*Corresponding Author: Rolf Ewers

Former Head of the University Hospital for Cranio-Maxillofacial-and Oral Surgery, Waehringer Guertel 18-20. 1090 Vienna, Austria.

Head of the CMF Institute Vienna, Roosevelt Platz 12 1090 Vienna, Austria.

Email: rolf@cmf-vienna.com

### Abstract

**Purpose:** The aim of these case reports is to report the outcomes of free revascularized fibula grafts functionally loaded with fixed, Fiber-Reinforced Composite (FRC) Full-Arch Prostheses (FA), on extra short implants considering: the fibula bone adaptation; Marginal Implant Bone Loss (MIBL); and overall implant survival.

**Patients and methods:** Tumor patients with free fibula grafts following partial mandibular resections were included in this report. Mesial and distal peri-implant bone levels were evaluated on panoramic radiographs, taken at the time of implant insertion (baseline) and at follow-up visits when FRC prostheses were evaluated. The bony adaptation of the fibula graft to its newly functional load was also evaluated.

**Results:** One male and one female patient with a mean age of 71 years, had a total of eight implants placed in Transplanted Revascularized Free Fibula Grafts (TRFFG) with an average follow-up period of 123.5 months (10.3 years) (shortest 122 months (10.2 years), longest 125 months [10.4 years]) were included. The implant survival rate was 100%, but one implant was not loaded, because it was placed outside the functional mandibular arch. Only one implant had visible bone level changes. Both transplanted fibula bones had significant morphological bone adaptations due to their functional loading. This phenomenon is better seen in the radiographs of the female patient.

**Conclusions:** Fixed, FRC full arch prostheses retained by four and three extra short implants provided: A comparatively cost-effective, safe, and stable prosthetic restoration of transplanted fibula bone. The overall implant survival rate and the MBL after, up to 10.4 years (125 months) are equivalent to those of threaded standard-length implants.

Received: Sep 19, 2023

Accepted: Nov 23, 2023

Published: Nov 30, 2023

Archived: www.jclinmedimages.org

Copyright: © Ewers R (2023).

**Keywords:** Ultra-short implants; locking taper and conus implants; mandibula reconstruction; free revascularized jejunal grafts; free revascularized fibula grafts; metal-free fiberglass-reinforced hybrid resin prostheses; CAD/CAM prostheses fabrication; bone transformation to functional load; fiber-reinforced composite full arch prosthesis.

## Introduction

Ablative surgery with and without radiation is the current standard therapy for oral cancer [1]. Mandibular defects can cause severe functional and aesthetic deformities, and the three-dimensional complexity of bone, soft tissue, skin, and neuromuscular structures make the reconstructive surgery a challenge for surgeons [2,3]. When partial mandible resection is required, patients may develop esthetic and functional defects such as: facial asymmetry; collapse of the mid face; inferior labial retraction; labial incompetence; salivary incontinence and difficulty in swallowing; limited oral aperture; deglutition; and speech articulation. All these severe sequelae generate a social, personal, and professional disability [4,5]. The goal of reconstructive surgery is to restore patients, with surgical ablation of the jaw, to their premorbid state [6]. Although there are numerous options for mandibular reconstruction, the fibula free flap has become the most popular vascularized graft to reconstruct composite or segmental defects in the mandible. This is due to: its versatility; predictability; and potential to be harvested as an osseous, myo-osseous, or osteo-cutaneous flap [7,8]. The type of reconstruction depends on several factors: Such as location of the defect; extension of the partial mandible resection; the type and extent of the intraoral and/or extraoral soft tissue defects present; and the general condition of the patient [8-10]. Ideally, skin, soft tissue mucosa and bone should be matched to the characteristics of the flap prior to performing the reconstruction. The reconstruction of the partially resected mandible can be done during the ablation of the tumor— we prefer this approach— followed by treatment of the mucosal defect with a jejunal free flap, and stabilization of the partially resected mandible with an osteosynthesis plate [11,12]. We perform the free fibula flap reconstruction of the partially resected mandible during a second stage operation [13]. Or perform the resection plus reconstruction with an osseous-cutaneous fibula free flap in a one stage operation [14]. The fibula has favorable bone quantity and quality for integration of dental implants, which facilitates the prosthetic rehabilitation [15,16]. Dental implants provide for an even distribution of the occlusal load on the mandible, which minimizes or prevents resorption of the bone graft. Survival of osseointegrated implants, and prosthetic rehabilitation of reconstructed mandibles is extensively documented in the literature [17-19]. However, due to limitations of the height and contour of the fibula there remains a significant surgical and prosthetic challenge [20]. Restoration of a full complement of teeth may require several staged procedures over a six-to-twelve-month period. The main disadvantage of fibula free flaps is their limited height of available host bone. The vertical height of the harvested bone is 1.3-2.3 cm [20,21]. To minimize the need for additional operative procedures, such as double-barreling or vertical distraction osteogenesis [4,22]. We decided to use extra SHORT® Bicon implants (Bicon LLC, USA) [23].

Evidence exists suggesting that short implants perform as well as longer implants for the rehabilitation of edentulous sites. Therefore, for the rehabilitation of atrophic sites, the use of extra short implants has a significant advantage, and often precludes the need for bone augmentation [24]. Overall, prospective studies now indicate similar survival and success rates for short and standard dental implants [25]. The all-on-4 concept is considered a safe treatment option with predictable

outcomes for the restoration of atrophic mandibles [26]. Implant success rates are usually above 90%, and their long-term survival rates are acceptable [27-29]. The cost-effective use of only four implants to support a prosthesis, and the possibility of immediate loading, provide important advantages [30]. Rehabilitation of free fibular grafts with dental implants can be even more challenging than treating atrophic mandibles [14]. Recently, the European Association of Dental Implantologists reached a consensus that short implants in atrophic sites are liable treatment option, and their risks are comparable to those of standard-dimension implants in combination with augmentation procedures [31-33]. A recent oral reconstruction foundation consensus report suggests that long cantilevers should be avoided in full-arch reconstructions of the posterior mandible with the use of short implants [34]. That said, the results of the present report, and the available evidence in the literature, indicate that the use of extra short implants in an all-on-4 setting in the mandible is a warranted and a viable treatment alternative [35,36]. In a recent pilot study, were ported the results of Full-Arch, (FRC) prostheses using a fixed-on-4 extra SHORT®5.0-mm implant approach [37-40]. The aim of the current report is to report the longer-term outcomes of splinted extra short implants in free fibula graft reconstructed mandibles, in terms of: The functional morphologic bone changes; adaptations; marginal bone level changes; and the overall survival of implants and prostheses.

## Patients, methods, and materials

After approval of the institution's ethical committee was granted (No. 018/2011), a prospective study was initiated according to the Declaration of Helsinki, as well as the Good Clinical Practice guidelines. The results are reported according to the STROBE (Strengthening the Reporting of Observational Studies in Epidemiology) criteria [41].

**Inclusion criteria:** Patients aged between 68 and 74 years with free fibula transplant reconstructed mandibles were included in this study after their written consent was obtained.

**Exclusion criteria:** The following exclusion criteria were adopted: presence of diabetes (hemoglobin A1c level >6.5%); smoking (>10 cigarettes per day); alcoholism; untreated periodontitis in the opposing jaw; history of bacterial endocarditis; reduced general state of health; bisphosphonate, interferon, or glucocorticoid intake; rheumatic disease; untreated tumor disease; osteomyelitis; pregnancy; poor patient compliance and physical limitations interfering with oral hygiene; as well as participation in other medical studies 30 days before implant insertion.

**Patient's medical history:** Both patients did not report about relevant medical, family, and psycho-social history including relevant genetic information. Both patients had a squamous cell carcinoma of the left partial tongue, floor of the mouth and alveolar ridge of the mandible. The diagnosis was confirmed by the histology evaluation of the biopsy. The dimension of the tumor was evaluated by Computer Tomography and Magnetic Resonance Imaging. PET scans revealed no metastasis of the localized squamous cell carcinoma. The episode of care organized, and the timeline are described below. As the patient's adherence was positive and they tolerated the Chemo- and Radiotherapy very well and the tumor operation with recon-

struction showed a good result, we decided to perform the fibula reconstruction as the patients had a good prognosis. As the therapy was very well tolerated and so successful, we did not have to make any changes in our therapeutic interventions. There were no adverse or unanticipated events. Both patients had been very satisfied with their multiple steps-therapy and their outcome. The detailed surgical and prosthetic protocols were reported elsewhere along with their results [39,40]. The implants healed while submerged and were uncovered after 3 months. Impressions were taken on the day of uncovering, and implants were loaded approximately two weeks later.

### Operating procedure

Both patients received local anesthesia. Four extra SHORT® implants (Bicon, 4x5 mm, (260-340-255), Bicon LLC, Boston, USA) were placed in the transplanted fibula grafts. A crestal incision was made in the transplanted fibula grafts in preparation for the osteotomies, using (Pilot Drill 260-101-001, and Latch Reamers 260-101-125 to -140) according to the Bicon implant slow-drilling protocol. The protocol also recommends placing the implants about 2.0 to 3.0 mm subcrestally (Figure 1). Ideal subcrestal placement was not always possible to achieve [42]. Following primary closure, all implants had an uneventful healing for at least 3 months before they were surgically uncovered.

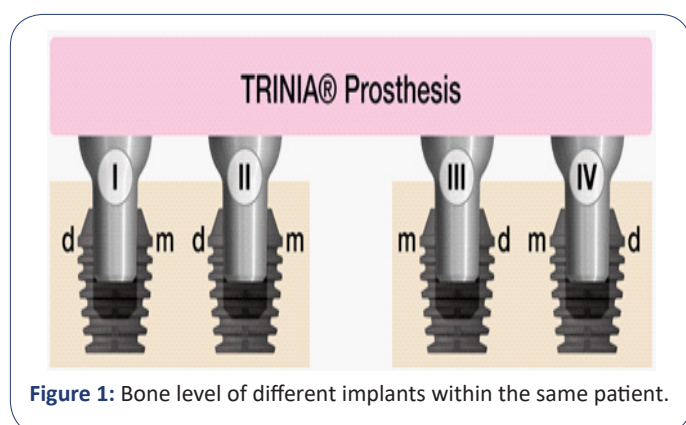


Figure 1: Bone level of different implants within the same patient.

### Prosthetic procedure

After uncovering the implants, a full arch implant-level transfer impression was made with four 2.5 mm impression posts and sleeves (260-100-413 and -414), and four Temporary PEEK Abutments with a 2.5 mm Post 260-340-745 to 260-340-765 were placed. Approximately 10 days later, a try-in teeth arrangement session to evaluate aesthetic and functional occlusion of the prosthesis was completed. After another ten days the final full arch prosthesis was placed. Patients had received universal abutments 260-240-710 to 260-265-725 (Bicon). The permanent full-arch CAD/CAM produced TRINIA prostheses were screw-retained with Hex Retention Screws (260-100-020) on Fixed-Detachable Abutments with 2.5 mm Posts (260-250-213 to -255).

### Prostheses description and evaluation

Frame works for the TRINIA™ prostheses were designed and milled from fiber-reinforced hybrid-resin composite 25.0 mm Ivory Discs (260-612-125) (TRINIA, Bicon LLC). Minimum FRC thicknesses were 2.0 mm around the abutments and 2.0 mm at the occlusal surface. Composite and acrylic resin teeth, as well as the polyceramic material, Ceramage (Shofu), were bonded onto the FRC framework.

### Implant recall

Subsequent to the implant loading appointment, patients returned for a six-month recall examination and on an annual basis. At each follow-up visit, the peri-implant tissues were examined, and a panoramic radiograph was taken. At patient recalls, their prostheses were evaluated for survival, which was defined as the prostheses remained in situ with, or without modification for the observation period.

### Results

A total of 2 patients with partially resected mandibles being reconstructed by means of a revascularized free fibula graft were included in this report, 1 woman and 1 man. The mean age was 71 years. The average follow-up period of 123.5 months (10.3 years) (shortest 122 months [10.2 years], longest 125 months [10.4 years]).

### Patient-based implant survival

No implant was lost, so the survival rate of the implants was 100%. However, one implant in the female patient could not be loaded, because it was positioned outside of the functional mandibular curvature. The cumulative implant survival rate was 100%.

### Morphological bone adaptations and changes

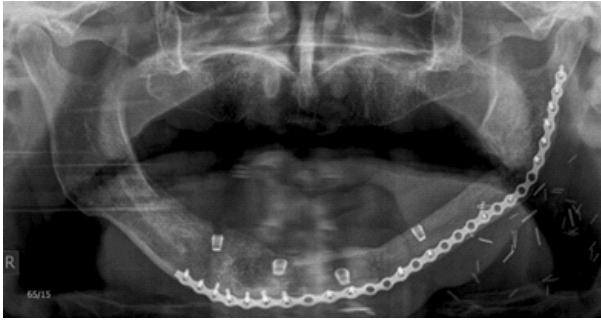
The well-known lack of the bone height in free fibula grafts being transplanted to the mandible [10,11]. Led to the decision to use extra short implants with locking-tapered fixed abutments, which are cold welded to the well of the implant resulting a bacterially sealed connection. During functional loading, the implants and abutments have micro movement as a single unit in the fibula bone. This results in several phenomena, which we shall demonstrate in the two following patient cases [33].

1. Changes of bone volume
2. Straightening of the cortex
3. Leveling defects in the cortex
4. Increase mineralization of the cortex
5. Changes of Gray Scale Value (GSV)
6. Marginal bone gain, if sub-crestally placed
7. Marginal bone loss, if not sub-crestally placed

**Patient cases:** Examples of Functional Morphologically Adapted Bone, Crestal Bone Gain, and Crestal Bone Loss: The first patient is a 68-year-old male with a squamous cell carcinoma of the mandible involving the gingiva, the left side of the tongue, the floor of the mouth, and mandibular region of what would be teeth #18 to 26. Six weeks after preoperative radio-chemotherapy 54 Gy, radical surgery was performed with partial resection of the mandible, from the mandibular angle to the region of what would be tooth #28 and included a primary microvascular reconstruction with an osteo-cutaneous fibula flap [13,43,44].

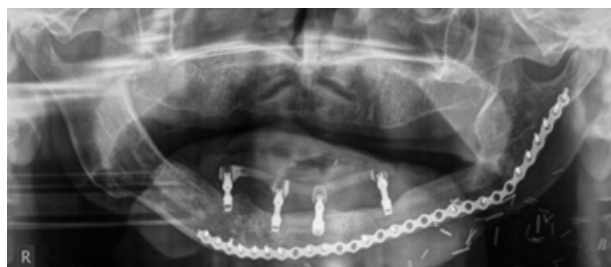Fourteen months later four implants, 4.0x5.0 mm calcium phosphate coated implants (extra SHORT® Implants, Integra-CP® surface treatment, Bicon LLC) (260-340-255), were inserted into the transplanted free vascularized fibula graft in regions #19,22,25 and 27 (Figure 2).



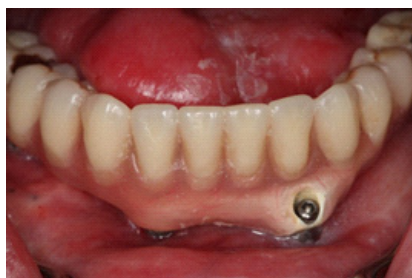

**Figure 2:** Panoramic radiograph of a 68-year-old patient after primary reconstruction with a free fibula graft and secondary implant insertion of four 4.0x5.0 mm extra SHORT® Bicon implants.

Six months later the four implants were uncovered, and a full arch implant-level transfer impression was made with four 2.5 mm Impression Posts and Sleeves (260-100-413 and -414). After the impression of the freshly uncovered implants, we inserted four Temporary PEEK Abutments with a 2.5 mm Post (260-340-745 to 260-340-765). After approximately 10 days, a try-in of the prosthesis was completed. After another 10 days, the permanent full-arch CAD/CAM produced TRINIA 12 tooth prosthesis was screw-retained with Hex Retention Screws (260-100-020) on Fixed-Detachable Abutments with 2.5 mm Posts (260-250-213 to -255) (Figure 3a and b).



**Figure 3a:** Panoramic radiograph at initial loading of a screw-retained fixation with Hex Retention Screws on Fixed-Detachable Abutments with 2.5 mm posts supporting the CAD/CAM produced TRINIA prosthesis.

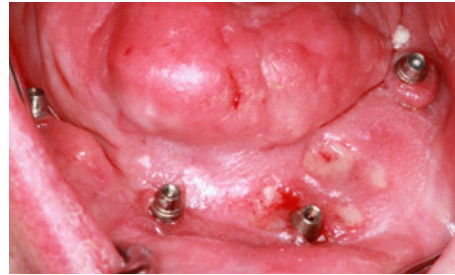


**Figure 3b:** Full-arch CAD/CAM produced TRINIA-12 teeth prosthesis, screw-retained with Hex Retention Screws (260-100-020) on Fixed-Detachable Abutments with 2.5 mm Posts.

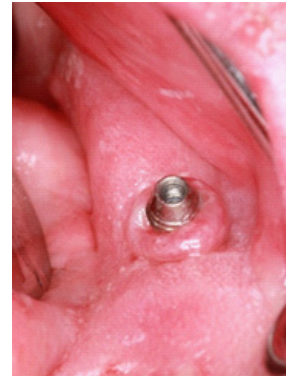Many authors report difficulties with the size of the fibula bone [38,39]. An additional problem is that the skin of the fibula flap is sometimes very thick, with considerable mobility, and many hair follicles and is thought to be prone to peri-mucositis and peri-implantitis. If the peri-implant tissue around the fibula transplant lacks keratinized gingiva, a soft tissue adjustment is necessary. In such cases Vestibuloplasty with the placement of free palatal gingival graft is the procedure of choice [14,45].

A few months after initial loading, we recognized early peri-mucositis around the implants 19,22 and 25 which were in the skin of the osteo-cutaneous fibula flap (Figure 4a and b). We performed a Vestibuloplasty with placement of a free gingival

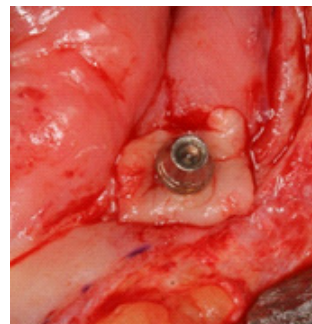
graft from the cheek region placed around the implants and in the fornix vestibule (Figure 5a and b) [46,47].



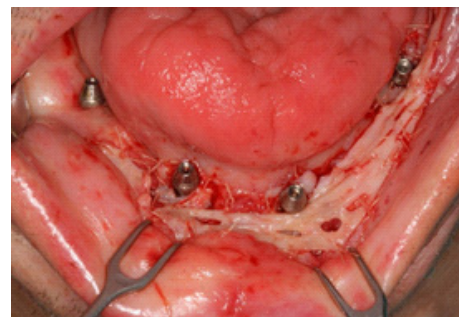
**Figure 4a:** Early peri-mucositis around the implant's region 19,22 and 25, in the skin of the flap area.



**Figure 4b:** The most pronounced peri-mucositis was present at the implant in region #19.

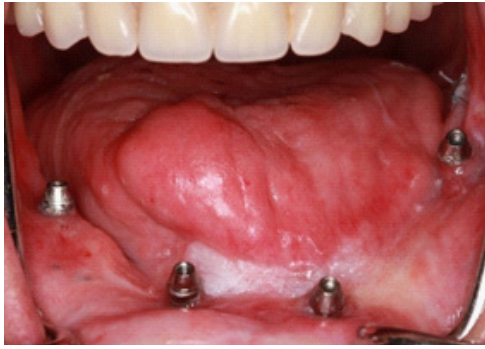


**Figure 5a:** Free mucosal flap from the left inner cheek around the implant in region #19.

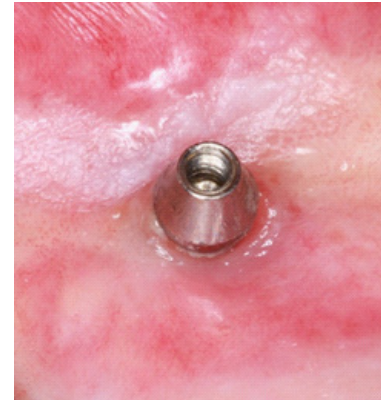


**Figure 5b:** Free mucosal flaps from the left and right inner cheek placed around the implants 19,22 and 25 and in the fornix vestibuli from region 19 to 25.

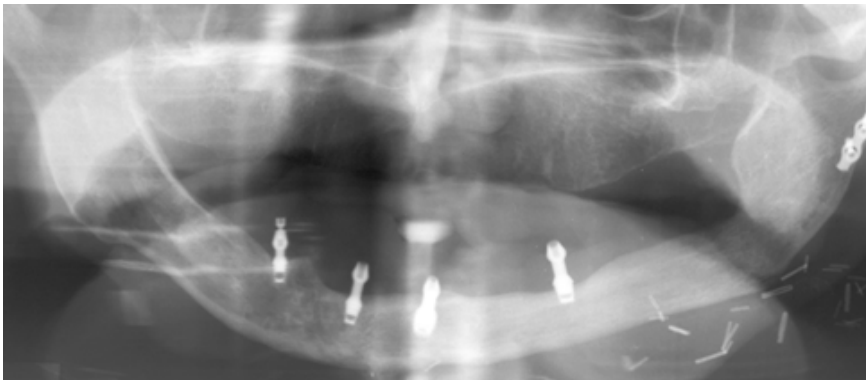The free gingival graft from the cheek region around the three implants and in the fornix vestibuli healed satisfactorily. At the 10.2-year recall session the peri-implant soft tissues were healthy (Figure 6a and b) and the radiological results were positive (Figure 7). Additionally, patient was very satisfied with his full arch TRINIA prosthesis.



**Figure 6a:** Intraoral appearance at the 10.2 years recall session. The full arch TRINIA prosthesis was removed by unfastening the Hex Retention Screws from the Fixed-Detachable Abutments. Note the healthy peri-implant mucosa before any oral hygiene treatment.



**Figure 6b:** Mucosa, 9 years after free mucosa transplant from the cheek region around implant region 22 before oral hygiene treatment.



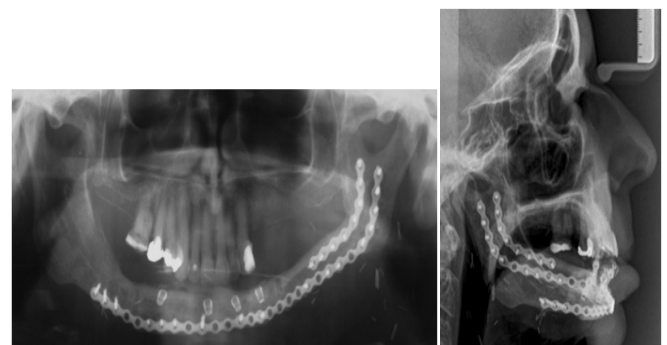
**Figure 7:** Panoramic radiograph at 10.2 years recall session. Two years prior to this session, the osteosynthesis plate had been partially removed. Note the crestal bone loss around the implant in the region 19, which had not been sub-crestally positioned.

**The following are observations regarding the male patient:**

1. The absence of keratinized gingiva around the implant in the #19 region most likely led to peri-mucositis, which is seldom seen around Bicon implants, but has been widely reported around implants with screw retained abutments [14,45,46].
2. The soft tissue peri-implant problems can be solved with free mucosal grafts from the inner cheek bilaterally.
3. Due to the longevity of function, the shape of the transplanted fibula adapted to an almost normal appearing mandibular body, comparable to the other side.
4. Because the patient had no opposing teeth, the functional morphological bone adaptation in the cortical section of grafted fibula was not as dramatic as was expected.
5. The protocol of the Bicon implant indicates the implant should be positioned at least 2.0-3.0 mm sub-crestally, [40,42]. Otherwise, you may observe crestal bone loss as seen in implant region 19.

The second patient, a 72-year-old female, presented with a squamous cell carcinoma on the left side of the mandible extending from the gingiva to part of the left tongue, the floor of the mouth, and the mandible from region from 17 to 27. After 7 weeks of preoperative radio-chemotherapy with 54 Gy, we performed radical surgery involving partial resection of the mandible, from the mandibular angle to region 27, and a primary micro vascular reconstruction with a vascularized jejunal flap to close the mucosa defect [11,48]. An osteosynthesis plate was used to stabilize the mandibular defect. After three years with-

out tumor recurrence, we reconstructed the mandibular defect with a vascularized fibula graft. One year later, we inserted four 4.0 x 5.0 mm calcium phosphate coated implants (extra SHORT® Implants, Integra-CP® surface treatment, Bicon LLC) (260-340-255) in region 20,22,25 and 28 (Figure 8a and b).

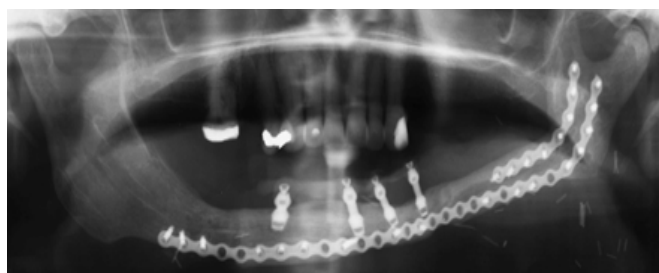


**Figure 8a and 8b:** Panoramic and lateral cephalometric radiograph after insertion of four 4.0x5.0 mm calcium phosphate coated extra SHORT® Bicon Implants into the fibula graft.

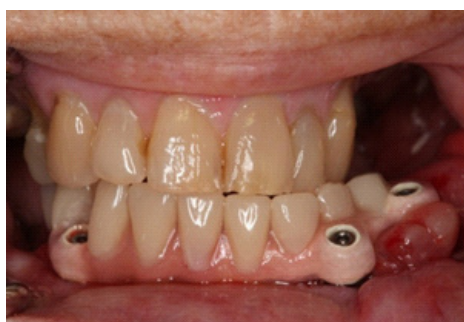Eight months later, the four implants were uncovered, and a full arch implant-level transfer impression was made with four 2.5 mm Impression Posts and Sleeves (260-100-413 and -414). After taking impressions of the freshly uncovered implants, we inserted four Temporary PEEK Abutments with a 2.5 mm Posts (260-340-745 to 260-340-765). Ten days later, a try-in teeth arrangement session of the prosthesis was performed to evaluate the aesthetic and functional occlusion. After another 10 days, the permanent full-arch CAD/CAM produced TRINIA-9 teeth



prosthesis was fastened using Hex Retention Screws (260-100-020) on Fixed-Detachable Abutments with 2.5 mm Posts (260-250-213 to -255) (Figure 9a and b).

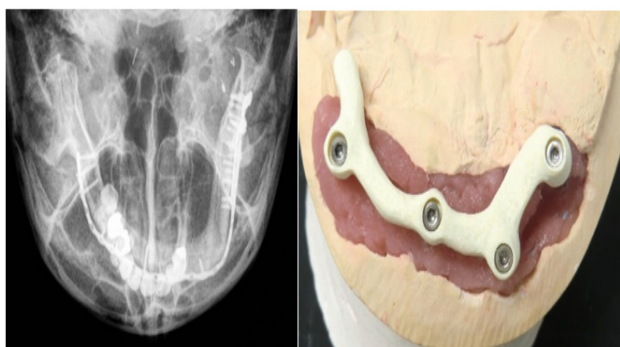


**Figure 9a:** Panoramic radiograph of the CAD/CAM produced TRINIA prosthesis at initial loading after screw-retained fixation with Hex Retention Screws on Fixed-Detachable Abutments using 2.5 mm Posts.



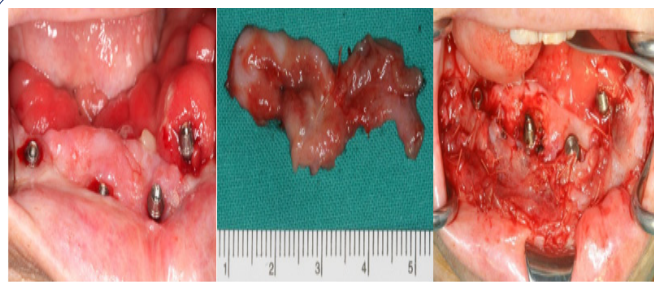**Figure 9b:** Full-arch CAD/CAM produced TRINIA-9 teeth prosthesis, fastened with Hex Retention Screws (260-100-020) on Fixed-Detachable Abutments with 2.5 mm Posts in class III occlusal relationship.

The resection operation resulted in an inadequate lower left lip and fornix vestibuli. Additionally, the curvature of the left mandible was not optimal (Figure 10a and b) and resulted in the left middle implant being mal positioned. This led to an unesthetic and unacceptable result for the female patient. Therefore, we decided to put this implant to sleep.



**Figure 10a and b:** Asymmetric curvature of the mandible and eccentric position of the left middle implant.

The peri-implant tissue around a jejunal transplant lacks keratinized gingiva; therefore, soft tissue adjustment may be necessary. Vestibuloplasty with placement of free jejunal mucosa graft is our procedure of choice using mucosa from the transplanted jejunum [47]. As stated in this case, due to the shallowness of the lower lip and fornix vestibuli, we decided to perform a Vestibuloplasty with placement of a free jejunal mucosa graft taken from the healed transplanted vascularized jejunal graft and placing it around the implants in region of 22 to 28; and in the fornix vestibuli to elongate the lower lip (Figure 11a to c).

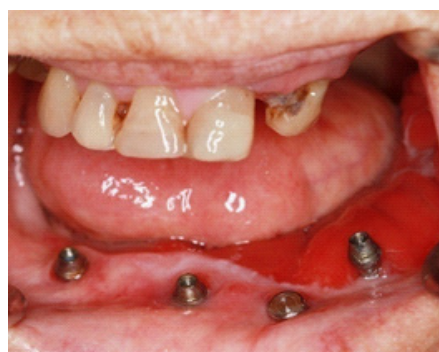

**Figure 11a:** Intraoral conditions before Vestibuloplasty after vascularized jejunal graft and insertion of the four implants.

**Figure 11b:** Free jejunal mucosa graft from the well healed former transplanted vascularized jejunal graft.

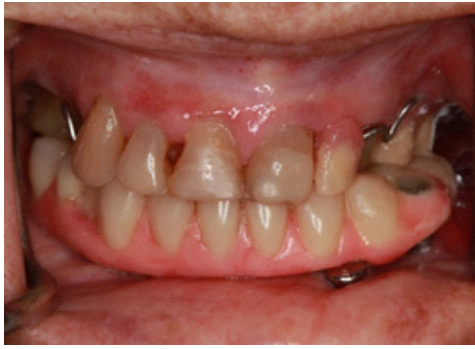**Figure 11c:** Intraoral view, after free mucosal Vestibuloplasty with mucosa from the former transplanted well healed jejunal graft to the alveolar crest around the implants in region 22 to 28 and in the fornix vestibuli in order to elongate the lower lip.

The course of healing was satisfactory, and the patient was free of tumor recurrence. Figure 12 shows the intraoral condition 102 months (8.5 years) after Vestibuloplasty with free jejunal mucosa graft.




**Figure 12:** Intraoral image taken 102 months (8.5 years) after the Vestibuloplasty with free jejunal mucosa graft before oral hygiene treatment.

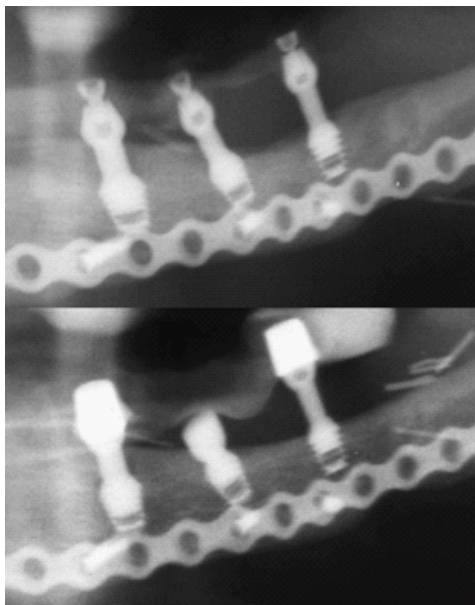
At her last recall session, 10.4 years after initial loading of the three implants, the site was healthy, and the patient was very satisfied with the full arch TRINIA prosthesis. There was no recurrence of peri-mucositis as shown in Figure 13. The radiographic evaluation of her last panoramic radiograph at 10.4 years control (Figure 14a and b) compared favorably to the one at initial loading (Figure 9a). The fibula bone has an almost round shape with about 4.0 to 5.0 mm thick cortical bone [24,14,20]. Due to the insertion of extra SHORT® implants and splinting the implants with the elastic framework, TRINIA® [49-52] there was an unexpectedly positive morphological bone adaptation due to functional loading [53-56]. This resulted in the leveling of the bony defect between the posterior and right middle implant and reshaping a cortical fibula cortex-like structure in the posterior part of the transplanted fibula. The flexibility of the TRINIA® prosthesis, probably increased as a result of having to put the mal-positioned middle implant to sleep; and the fact that the patient had at least at the beginning opposing natural teeth, though in a cross-bite relationship. The patient was very satisfied with this result as she could chew as before the tumor operation.



**Figure 13:** Intraoral view at 10.4 years recall session before oral hygiene treatment.



**Figure 14a:** Panoramic radiograph at initial loading (above) (Figure 9a) and at the last recall session 10.4 years after initial loading of the three implants (below).



**Figure 14b:** Magnified section of the panoramic radiographs of Figure 14a at initial loading (above) (Figure 9a) and at the last recall session 10.4 years after initial loading of the three implants (below).

#### Following observations could be made in this case:

1. It is possible to leave locking tapered Bicon implants surrounded with loose jejunal mucosa as seen in Figure 11a and 12; however, it was better to transplant free jejunal mucosa to get a more fixed mucosa tissue, which keratinizes slowly, and allows for elongation of the lip, if necessary.
2. Due to the longevity of function in this case, the shape of the transplanted fibula adapted more and more into a bi-cortical fibula.

3. As a result of splinting the implants with the elastic framework TRINIA® [49-52] there was morphological bone adaptation due to functional loading [53-56]. With leveling the bony defect between the posterior and right middle implant and reshaping a cortical fibula cortex structure like the posterior part of the transplanted fibula.

4. Since the patient had opposing teeth, the functional morphological bone adaptation was dramatic in the cortical section of the former fibula cortex developing an almost normal looking fibula cortex.

5. As stated in its protocol, the Bicon implant should be at least 2.0-3.0 mm sub-crestally positioned, [39,40]. Otherwise, you will observe less crestal bone gain as seen in the left posterior implant compared to the right middle implant.

#### Discussion

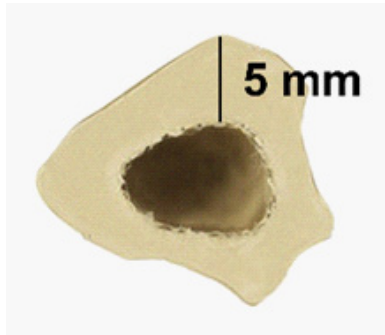
The aim of this report was to show the up to 10.4 year follow-up results of fixed, full-arch prostheses using a fiber-reinforced composite frameworks supported by 4.0x5.0 mm extra short implants in vascularized fibula grafts. The cumulative 10.3 year implant-based survival rate in this report was 100%, which is consistent with a recent study reporting excellent results of implant-fixed prostheses supported by extra short implants [35,57]. These results compare favorably with the results of prostheses fixed on implants of standard lengths [29,58]. Recent studies have reported that 4 implants were sufficiently stable to support an over denture in the short-term and that the tilting of implants did not alter the peri-implant MBLs compared with conventional, axially inserted implants [32,59-62].

In the female patient of this report, the left medial implant had to be put to sleep, shortly after initial loading for to aesthetic considerations. The patient had been using/loading her fiber-reinforced composite full-arch TRINIA® prosthesis on only three implants for 129 months (10.75 years) until she passed away. In the meantime, there are reports about positive results using only three extra SHORT® implants [59,63,64]. It has been shown that the observed occlusal force on each implant increases with fewer implants supporting a fixed prosthesis in the mandible. When the number of supporting implants is gradually reduced from 6 to 3 implants, the highest bending forces were found when only 3 implants were supporting the prosthesis. After 125 months (10.4 years) of initial loading, the remaining three implants in our patient showed an uneventful follow-up.

Revascularized free fibula grafts often are described as the workhorse of reconstructing resected mandibles [6,20,21]. The often-reported difficulties with the amount of the transplanted bone and the 4.0-5.0 mm thin cortical structure of the fibula (Figure 15) [5,13,65]. Are not a problem when using the extra SHORT® Bicon implants. In the last 13 years, it has been our experience that the shortness of the Bicon implants is a significant advantage for bone modeling and remodeling due to the implant's micro movement in the bone, which increases their functional load [40,56,63,64,66-68].

The (MBL) values remained stable in both patients on both mesial and distal sides of the implants. These values are comparable with those of implants of standard lengths [32,59,60,69]. The design of this extra SHORT® implant presents a double platform switch that was designed to load bone coronal to the implant-abutment interface through the base of the abutment. In this platform design, an implant shoulder gradually slopes inward and coronally toward the implant-abutment interface





**Figure 15:** Cross section of a fibula with 4.0 to 5.0 mm thickness of cortical bone.

creating space for crestal bone, while the base of the implant abutment presents a loading surface through which compressive loads are exerted on existing or potential crestal bone [70].

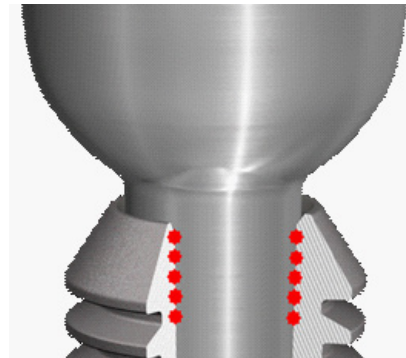
Only one implant had visible bone level changes. Both transplanted fibula bones had significant morphological bone adaptations due to functional loading consistent with Wolff's law [53-56]. This phenomenon is especially seen in the female patient. The Gray Scale Value (GSV) has decreased translucency meaning increased mineralization. Trabecular formation can be seen as well.

Crestal bone gain is mostly seen in un-splinted implants [71]. This phenomenon is seldom seen in splinted implants except when the prostheses are flexible, as with the TRINIA® material. Although the clinical significance of mandibular deformation is not fully understood, three different and simultaneous patterns of mandibular deformation have been reported to take place immediately upon mouth opening and closing. Therefore, one may not exclude the fact that harmful strains at the implant-bone interface are due to the use of a rigid prosthesis framework, indicating some forms of splinting may be a factor fostering marginal bone loss [72]. The FRC material used as framework in the current report is more compliant to mandibular deformation due to its similarity to the modulus of elasticity of cortical bone when compared to chromium cobalt (240GPa), or zirconia (200GPa), [49-51]. The impact of prosthetic materials on marginal bone level warrants future clinical investigations.

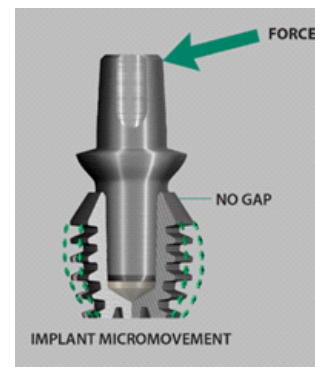
The MBL of mesial and distal implants was significantly influenced by the insertion depth of the implant. Contrary to recent findings, implants performed better, when they were placed in a slightly sub-crestal position (bone level to implant shoulder) [73-78]. In contrast to threaded implants, locking-taper implants which were placed slightly sub-crestally showed stable MBL values. Fixed, full-arch, FRC prostheses retained by three or four extra SHORT® implants provide a comparatively cost-effective, safe, stable alternative for prosthetic restoration of mandibular fibula grafts. In this report the overall implant survival rate and the MBL after up to 10.2 years are equivalent to those of implants of conventional lengths. Further, results of this report imply that extra SHORT® Bicon implants should be placed, as explained in the Bicon protocol, in a slightly sub-crestal position to achieve optimal results.

In one patient, we transplanted an osteo-cutaneous fibula flap and in the other a jejunal mucosa. We observed significant differences in peri-implant tissue behavior between both approaches. All the available literature recommends free keratinized mucosa transplants because the skin of the fibula flap is thick and sometimes, shows considerable mobility, and may

have hair follicles. Additionally, peri-implant soft tissue is prone to peri-mucositis [14,45,57,69]. Jejunal mucosa does resist peri-mucositis. However, it is better to replace loose jejunal mucosa with a free mucosa graft taken from the healed transplanted jejunal graft [47]. This procedure turned out to be very successful in our female patient.



**Figure 16:** Due to cold welding, the abutment has a self-locking connection with the implant: hence the abutment and the implant perform as a single unit.



**Figure 17:** Zipprich et al. [79,80]. shows in his radiographic movies with Bicon implants, that there is no movement between abutment and its implant. With transversal loading of the abutment, therefore, there will be micro-movements of the short implant.

## Conclusion

The shortness and the locking taper design of these extra SHORT® Bicon implants show the advantages of this special implant system.

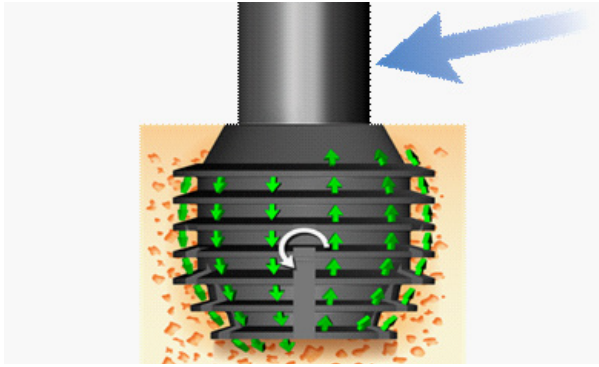
1. The cold welding of the conical abutment in the straight implant well results in a fixed immovable connection (Figure 16) and when the integrated abutment crown is loaded, the implant is also loaded (Figure 17) [79-81].

2. Because of the stability of the abutment/implant connection the implant itself exhibits micromovements of the implant in the bone (Figure 18) in turn this leads to modeling and remodeling and sometimes stimulates bone gain [63,64]. Additionally the extra SHORT® implants have a better stress distribution than standard long implants (Figure 19) [82,83].

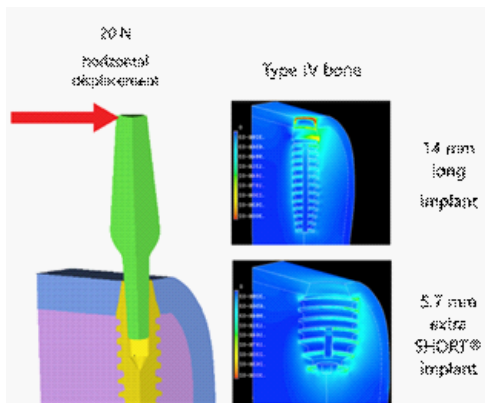
3. The 4.0-5.0 mm thin cortical bone of the fibula is not a disadvantage when inserting Bicon SHORT® implants, since these implants are stable in a minimal thickness of cortical bone.

4. The stability of the extra SHORT® implants and the flexibility of the CAD/CAM produced TRINIA full arch prosthetic reconstruction led to positive bone modeling and remodeling





**Figure 18:** Due to his finite element analyses, Müftü [82,83] postulates; therefore, that short and, especially the extra SHORT® Bicon implants show a circular like movement during horizontal and vertical loading.



**Figure 19:** Finite element analyses by Müftü, reveal [82,83] that short implants have a contralateral reaction to transversal displacements, even at the tip of the implant unlike standard long implants as seen in the images above, with displacement on the other side of the implant, there will be pressure on the contralateral side extending to the tip of the short implant.

during functional loading consistent with Wolff's [53-56] and Frost's laws [66-68].

5. With these two patients, we were able to observe the importance of adequate implant and prosthetic devices to enable bone to react positively with its modelling and remodeling ability according to Wolff's [53-56] and to Frost's laws [66-68].

## References

1. Roumanas ED, Garrett N, Blackwell KE, Freymiller E, Abemayor E, et al. Masticatory and swallowing threshold performances with conventional and implant-supported prostheses after mandibular fibula free-flap reconstruction. *J Prosthet Dent.* 2006; 96: 289-297.
2. Goiato MC, Ribeiro AB, Dreifus Marinho ML. Surgical and prosthetic rehabilitation of patients with hemimandibular defect. *J Craniofac Surg.* 2009; 20: 2163-2167.
3. Peled M, El-Naaj IA, Lipin Y, Ardekian L. The use of free fibular flap for functional mandibular reconstruction. *J Oral Maxillofac Surg.* 2005; 63: 220-224.
4. Chiapasco M, Brusati R, Galioto S. Distraction osteogenesis of a fibular revascularized flap for improvement of oral implant positioning in a tumor patient: a case report. *J Oral Maxillofac Surg.* 2000; 58: 1434-1440.
5. Navarro Cuellar C, Caicoa SJ, Acero Sanz JJ, Navarro Cuellar I, Muela CM, et al. Mandibular reconstruction with iliac crest free flap, nasolabial flap, and osseointegrated implants. *J Oral Maxil-*

*lofac Surg.* 2014; 72: 1226.e1-15.

6. Patel A, Harrison P, Cheng A, Bray B, Bell RB, et al. Fibular Reconstruction of the Maxilla and Mandible with Immediate Implant-Supported Prosthetic Rehabilitation: Jaw in a Day. *Oral Maxillofac Surg Clin North Am.* 2019; 31: 369-386.
7. Hidalgo DA. Fibula free flap: A new method of mandible reconstruction. *Plast Reconstr Surg.* 1989; 84: 71-79.
8. Urken ML, Buchbinder D, Costantino PD, Sinha U, Okay D, et al. Oromandibular reconstruction using microvascular composite flaps: Report of 210 cases. *Arch Otolaryngol Head Neck Surg.* 1998; 124: 46-55.
9. Coleman JJ 3rd. Microvascular approach to function and appearance of large orbital maxillary defects. *Am J Surg.* 1989; 158: 337-341.
10. Futran ND, Mendez E. Developments in reconstruction of midface and maxilla. *Lancet Oncol.* 2006 ; 7: 249-258.
11. Giovanoli P, Frey M, Schmid S, Flury R. Free jejunum transfers for functional reconstruction after tumour resections in the oral cavity and the pharynx: changes of morphology and function. *Microsurgery.* 1996; 17: 535-544.
12. Andrades P, Bohannon IA, Baranano CF, Wax MK, Rosenthal E, et al. Indications and outcomes of double free flaps in head and neck reconstruction. *Microsurgery.* 2009; 29:171-177.
13. Klug C, Berzacz D, Voracek M, Enislidis G, Rath T, et al. Experience with microvascular free flaps in preoperatively irradiated tissue of the oral cavity and oropharynx in 303 patients. *Oral Oncol.* 2005; 41: 738-746.
14. Attia S, Wiltfang J, Pons-Kuehnemann J, Wildbrand JF, et al. Survival of dental implants placed in vascularised fibula free flaps after jaw reconstruction, *Journal of Cranio-Maxillo-Facial Surgery.* 2018. <https://doi.org/10.1016/j.jcms.2018.05.008>
15. Chang YM, Santamaria E, Wei FC, et al. Primary insertion of osseointegrated dental implants into fibula osteoseptocutaneous free flap for mandible reconstruction. *Plast Reconstr Surg.* 1998; 102: 680-688.
16. Jackson RS, Price DL, Arce K, et al. Evaluation of clinical outcomes of osseointegrated dental implantation of fibula free flaps for mandibular reconstruction. *JAMA Facial Plast Surg.* 2016; 18: 201-206.
17. Bodard AG, Be'emer J, Gourmet R, et al. Dental implants and free fibula flap: 23 patients. *Rev StomatolChirMaxillofac.* 2011; 112: e1-e4.
18. Oteri G, Saverio De Ponte F, Pisano M, et al. Five years follow-up of implant-prosthetic rehabilitation on a patient after mandibular ameloblastoma removal and ridge reconstruction by fibula graft and bone distraction. *Dent Res J (Isfahan).* 2012; 9: 226-232.
19. Kramer FJ, Dempf R, Bremer B. Efficacy of dental implants placed into fibula-free flaps for orofacial reconstruction. *Clin Oral Implants Res.* 2005; 16: 80-88.
20. Khachatryan L, Khachatryan G, Hakobyan G. The Treatment of Lower Jaw Defects Using Vascularized Fibula Graft and Dental Implants. *J Craniofac Surg.* 2018; 29: 2214-2217.
21. Disa JJ, Winters RM, Hidalgo DA. Long-term evaluation of bone mass in free fibula flap mandible reconstruction *Am. J. Surg.* 1997; 174: 503-506.
22. Bahr W, Stoll P, Wachter R. Use of the "double barrel" free vascularized fibula in mandibular reconstruction. *J Oral Maxillofac*

- Surg. 1998; 56: 38–44.
23. Al-Johany SS, Al Amri MD, Alsaeed S, Alalola B. Dental Implant Length and Diameter: A Proposed Classification Scheme. *J Prosthodont.* 2017; 26: 252-260.
  24. Guida L, Bressan E, Cecoro G, Volpe AD, Del Fabbro M, et al. Short versus Longer Implants in Sites without the Need for Bone Augmentation: A Systematic Review and Meta-Analysis of Randomized Controlled Trials. *Materials (Basel).* 2022; 15: 3138.
  25. Thoma DS, Zeltner M, Hüsler J, Hämmerle CH, Jung RE, et al. EAO Supplement Working Group 4 - EAO CC 2015 Short implants versus sinus lifting with longer implants to restore the posterior maxilla: a systematic review. *Clin Oral Implants Res.* 2015; 26: 154-169.
  26. Malo P, Rangert B, Nobre M: 'All-on-four' immediate- function concept with Branemark System implants for completely edentulous mandibles: A retrospective clinical study. *Clin Implant Dent Relat Res* 2003; 5: 2.
  27. Malo P, Rangert B, Nobre M: 'All-on-four' immediate- function concept with Bran mark System implants for completely edentulous mandibles: A retrospective clinical study. *Clin Implant Dent Relat Res* 2003; 5: 2.
  28. Weinstein R, Agliardi E, Fabbro MD, et al. Immediate rehabilitation of the extremely atrophic mandible with fixed full prosthesis supported by four implants. *Clin Implant Dent Relat Res.* 2012; 14: 434,
  29. Patzelt SB, Bahat O, Reynolds MA, Strub JR, et al. The all-on- four treatment concept: A systematic review. *Clin Implant Dent Relat Res.* 2014; 16: 836,
  30. Agliardi E, Panigatti S, Clericò M, Villa C, Malò P, et al. Immediate rehabilitation of the edentulous jaws with full fixed prostheses supported by four implants: interim results of a single cohort prospective study. *Clin Oral Implants Res.* 2010; 21:459-465.
  31. Neugebauer J, Vizethum F, Berger C, et al. Update: Kurze, angulierte und durchmesserreduzierte Implantate— Praxisleitfaden: 11. Europäische Konsensuskonferenz (EuCC). *BDIZ/EDI Konkret.* 2016; 20: 88.
  32. Annibali S, Cristalli MP, Dell' Aquila D, Bignozzi I, La Monaca G, Pilloni A, et al. Short dental implants: a systematic review. *J Dent Res.* 2012; 91: 25-32.
  33. Palacios JAV, Garcia JJ, Carames JMM, Quirynen M, da Silva Marques DN, et al. Short implants versus bone grafting and standard-length implants placement: a systematic review. *Clin Oral Investig.* 2018; 22: 69-80.
  34. Schwarz F. et al. Recommendations for Implant-Supported Full-Arch Rehabilitations in Edentulous Patients: The Oral Reconstruction Foundation Consensus Report. *Int J Prosthodont.* 2021; 34: s8-s20.
  35. Esposito M, Pistilli R, Barausse C, Felice P, et al. Three-year results from a randomized controlled trial comparing prostheses supported by 5 mm long implants or by longer implants in augmented bone in posterior atrophic edentulous jaws. *Eur J Oral Implantol Winter.* 2014; 7: 383-395.
  36. Seemann R, Marincola M, Seay D, Perisanidis C, Barger N, Ewers R, et al. Preliminary results of fixed, fiber-reinforced resin bridges on four 4- x 5-mm ultrashort implants in compromised bony sites: A pilot study. *J Oral Maxillofac Surg.* 2015; 73: 630,
  37. Ewers R, Perpetuini P, Morgan V, Marincola M, Wu R, et al. TRINIA™— Metal-free restorations. *Implants.* 2017; 1: 02-07.
  38. Ewers R, Marincola M, Perpetuini P, Seemann R. Leichtgewicht im Praxistest: Restauration bei schwierigen Situationen und atrophien Kiefern. *Z Oral Implant.* 2017; 1/17: 28-36.
  39. Seemann R, Wagner F, Marincola M, Ewers R. Fixed Fiber-Reinforced Resin Bridges on 5.0 mm Implants in Severely Atrophic Mandibles: up to 5 Years' Follow-Up of a Prospective Cohort Study. *J Oral Maxillofac Surg.* 2018; 76: 956-962. <https://doi.org/10.1016/j.joms.2017.11.043>
  40. Ewers R, Marincola M, Perpetuini P, Morina A, Bergamo ETP, et al. Severely Atrophic Mandibles Restored With Fiber-Reinforced Composite Prostheses Supported by 5.0-mm Ultra-Short Implants Present High Survival Rates Up To Eight Years. *J Oral Maxillofac Surg.* 2022; 80: 81-92.
  41. Vandenbroucke JP, Von Elm E, Altman DG, Gøtzsche PC, Mulrow CD, et al. Iniciativa STROBE. Mejorar la comunicación de estudios observacionales en epidemiología (STROBE): explicación y elaboración [Strengthening the reporting of observational studies in epidemiology (STROBE): Explanation and elaboration]. *Gac Sanit.* 2009; 23:158.
  42. Morgan VJ. *The Bicon Short Implant: A Thirty-Year Perspective.* Chicago: Quintessence Publishing, 2017: 1 - 325.
  43. Millesi W, Glaser C, Klug C, Dobrowsky W, Pötter R, et al. Preoperative radiochemotherapy with radical surgery and primary microvascular reconstruction in the treatment of oral cancer. *Oral Oncology* 2001; 37: 1: 71. (Abstracts of the 7th Intern. Congress on Oral Cancer, The Hague, Netherlands, 22. – 26.04.2001)
  44. Yadav PS, Ahmad QG, Shankhdhar VK, Nambi GI, et al. Successful management of free osteocutaneous fibula flap with anomalous vascularity of the skin paddle. *Indian J Plast Surg.* 2009; 42: 255-257.
  45. Wei FC, Santamaria E, Chang YM, Chen HC. Mandibular reconstruction with fibular osteoseptocutaneous free flap and simultaneous placement of osseointegrated dental implants. *J Craniofac Surg.* 1997; 8: 512-521.
  46. Massarelli O, Baj A, Gobbi R, Soma D, Marelli S, et al. Cheek mucosa: A versatile donor site of myomucosal flaps. Technical and functional considerations. *Head Neck.* 2013; 35: 109-117.
  47. Feng GM, Yang WG, Huan-Tang Chen S, Chu YM, Tsai LM, et al. Periodic alterations of jejunal mucosa morphology following free microvascular transfer for pharyngoesophageal reconstruction. *J Plast Reconstr Aesthet Surg.* 2006; 59:1312-1317.
  48. Piza H, Ehrenberger K, Roka R, Wicke W, et al. Neue Methode zur chirurgischen Stimmrehabilitation: Mikrochirurgische Jejunum-Transplantation. *Handchir Mikrochir Plast Chir* 1. 1986; 8: 291–294.
  49. Bonfante EA, Suzuki M, Carvalho RM, Hirata R, Lubelski W, et al. Digitally produced fiber-reinforced composite substructures for three-unit implant-supported fixed dental prostheses. *Int J Oral Maxillofac Implants.* 2015; 30: 321-329.
  50. Bonfante EA, Coelho PG. A Critical Perspective on Mechanical Testing of Implants and Prostheses. *Adv Dent Res.* 2016; 28:18-27.
  51. de Oliveira Lino LF, Machado CM, de Paula VG, Vidotti HA, Coelho PG, et al. Effect of aging and testing method on bond strength of CAD/CAM fiber-reinforced composite to dentin. *Dent Mater.* 2018; 34: 1690-1701.
  52. Bergamo ETP, Yamaguchi S, Lopes ACO, Coelho PG, de Araújo-Júnior ENS, et al. Performance of crowns cemented on a fiber-reinforced composite framework 5-unit implant-supported prostheses: In silico and fatigue analyses. *Dent Mater.* 202; 37: 1783-1793.

53. Wolff J. The classic: On the significance of the architecture of the spongy substance for the question of bone growth: A preliminary publication. 1869. *Clin Orthop Relat Res.* 2011; 469: 3077-3078.
54. Wolff J. The classic: On the inner architecture of bones and its importance for bone growth. 1870. *Clin Orthop Relat Res.* 2010; 468:1056-1065.
55. Wolff J. The classic: on the theory of fracture healing. 1873. *Clin Orthop Relat Res.* 2010; 468: 1052-1055.
56. Wolff J. *Das Gesetz der Transformation der Knochen.* Berlin: Verlag von August Hirschwald. 1892.
57. Lozano Carrascal N, Anglada Bosqued A, Salomó Coll O, Hernández Alfaro F, Wang HL, et al. Short implants (<8 mm) versus longer implants (≥8 mm) with lateral sinus floor augmentation in posterior atrophic maxilla: A meta-analysis of RCT's in humans. *Med Oral Patol Oral Cir Bucal.* 2020; 25: e168-e179.
58. Afrashtehfar KI. The all-on-four concept may be a viable treatment option for edentulous rehabilitation. *Evid Based Dent.* 2016; 17: 56-57.
59. Duyck J, Van Oosterwyck H, Vander Sloten J, De Cooman M, Puers R, et al. Magnitude and distribution of occlusal forces on oral implants supporting fixed prostheses: An in vivo study. *Clin Oral Implants Res.* 2000; 11: 465-475.
60. Francetti L, Romeo D, Corbella S, Taschieri S, Del Fabbro M, et al. Bone level changes around axial and tilted implants in full-arch fixed immediate restorations. Interim results of a prospective study. *Clin Implant Dent Relat Res.* 2012; 14: 646-654.
61. Mocanu RG, Florica LI, Preoteasa CT, Meghea MD, Preoteasa E, et al. Periimplant Bone Resorption at the Level of Tilted Implants in SKY Fast & Fixed Restorations. *J Med Life.* 2020; 13: 336-341.
62. Galindo Moreno P, León Cano A, Ortega Oller I, Monje A, O Valle F, et al. Marginal bone loss as success criterion in implant dentistry: beyond 2 mm. *Clin Oral Implants Res.* 2015; 26: e28-e34.
63. Ewers R, Marincola M, Perpetuini P. Treating the atrophic maxilla with four, three, or even one ultrashort implant. *J Dent Maxillofacial Res.* 2021; 3: 43-58.
64. Yu-Chi Cheng, Paolo Perpetuini, Laura Murcko, Muneki Hirayama, Katherine Morgan, et al. Fiber-Reinforced Composite Full-arch Prosthetic Reconstructions Supported by Three Standard, Short or Extra-Short Implants: a Two-Center Retrospective Study *Clin Oral Invest* (2023) (in review).
65. Zlotolow IM, Huryn JM, Piro JD, Lenchewski E, Hidalgo DA. Osseointegrated implants and functional prosthetic rehabilitation in microvascular fibula free flap reconstructed mandibles. *Am J Surg.* 1992; 164: 677-681.
66. Frost HM: *The Utah Paradigm of Skeletal Physiology* Vol. 1, IS-MNI, 1960.
67. Frost HM: *The Utah Paradigm of Skeletal Physiology* Vol. 2, IS-MNI, 1960.
68. Frost H. The Utah paradigm of skeletal physiology: An overview of its insights for bone, cartilage and collagenous tissue organs. *J Bone Miner Metab.* 2000; 18: 305-316. <https://doi.org/10.1007/s007740070001>
69. Maceiras L, Liñares A, Nóvoa L, Batalla P, Mareque S, et al. Marginal changes at bone-level implants supporting fixed screw-retained partial implant prostheses with or without intermediate standardised abutments: 1-year results of a randomised controlled clinical trial. *Clin Oral Implants Res.* 2023.
70. Urdaneta RA, Seemann R, Dragan IF, Lubelski W, Leary J, et al. A retrospective radiographic study on the effect of natural tooth-implant proximity and an introduction to the concept of a bone-loading platform switch. *Int J Oral Maxillofac Implants.* 2014; 29: 1412-1424.
71. Urdaneta RA and Chuang SK. The Survival of Short and Ultra-short Plateau Root Form Implants. In: *Short Implants*, Tomasetti BJ and Ewers R (eds.), Springer Nature Switzerland AG. 2020; 95 – 124. [https://doi.org/10.1007/978-3-030-44199-9\\_8](https://doi.org/10.1007/978-3-030-44199-9_8)
72. Abdel-Latif HH, Hobkirk JA, Kelleway JP. Functional mandibular deformation in edentulous subjects treated with dental implants. *Int J Prosthodont.* 2000; 13: 513-519.
73. Hartman GA, Cochran DL: Initial implant position determines the magnitude of crestal bone remodeling. *J Periodontol.* 2004; 75: 572.
74. Caetano GM, Pauletto P, Mezzomo LA, Rivaldo EG. Crestal Bone Changes in Different Implants Designs: A Prospective Clinical Trial. *Eur J Dent.* 2019; 13: 497-502.
75. Nickenig HJ, Wichmann M, Schlegel KA, et al. Radiographic evaluation of marginal bone levels adjacent to parallel-screw cylinder machined-neck implants and rough-surfaced micro-threaded implants using digitized panoramic radiographs. *Clin Oral Implants Res.* 2009; 20: 550-554.
76. Cassetta M, Pranno N, Calasso S, et al. Early peri-implant bone loss: A prospective cohort study. 2015; 44: 1138-1145.
77. Wagner F, Schuder K, Hof M, et al. Does osteoporosis influence the marginal peri-implant bone level in female patients? A cross-sectional study in a matched collective. *Clin Implant Dent Relat Res.* 2017; 19: 616-623.
78. Pellissier E, Desoutter A, Chaux Bodard AG. Peri implant bone resorption on microvascular free fibula flap: A radiographic retrospective study. *J Oral Med Oral Surg* 2020; 26: 11.
79. Zipprich H, Weigl P, Ratka C, Lange B, Lauer HC, et al. The micro-mechanical behavior of implant-abutment connections under a dynamic load protocol. *Clin Implant Dent Relat Res.* 2018; 20: 814-823.
80. Zipprich H, Rathe F, Pinz S, Schlotmann L, Lauer HC, et al. Effects of Screw Configuration on the Preload Force of Implant-Abutment Screws. *Int J Oral Maxillofac Implants.* 2018; 33: e25-e32.
81. Rathe F, Ratka C, Kaesmacher C, Winter A, Brandt S, et al. Influence of different agents on the preload force of implant abutment screws. *J Prosthet Dent.* 2021; 126: 581-585.
82. Chou HY, Müftü S, Bozkaya D. Combined effects of implant insertion depth and alveolar bone quality on periimplant bone strain induced by a wide-diameter, short implant and a narrow-diameter, long implant. *J Prosthet Dent.* 2010; 104: 293-300.
83. Bozkaya D, Muftu S, Muftu A. Evaluation of load transfer characteristics of five different implants in compact bone at different load levels by finite elements analysis. *J Prosthet Dent.* 2004; 92: 523-530.