

Case Report

Open Access, Volume 3

Early symptoms and signs of bony and brain lesions associated with hyperhomocysteinemia: Evidence with scintigraphic images of skeleton and brain

Hsuan-Hsuan Hsu¹; Chia-Yuan Guo¹; Danielle Anne G Tee¹; Tsan-Yu Huang¹; Chia-Ying Lai²; Chih-Cheng Hsu³; Shin-Tsu Chang^{2,4*}

¹School of Medicine, National Defense Medical Center, Taipei, Taiwan.

²Department of Physical Medicine and Rehabilitation, Tri-Service General Hospital, Department of Physical Medicine and Rehabilitation, School of Medicine, National Defense Medical Center, Taipei, Taiwan.

³Department of Neurology, Jiannren Hospital, Kaohsiung, Taiwan.

⁴Department of Physical Medicine and Rehabilitation, Kaohsiung Veterans General Hospital, Kaohsiung, Taiwan.

*Corresponding Author: Shin-Tsu Chang

Department of Physical Medicine and Rehabilitation,
Kaohsiung Veterans General Hospital, Kaohsiung, Taiwan;
Department of Physical Medicine and Rehabilitation,
Tri-Service General Hospital, School of Medicine,
National Defense Medical Center, Taipei, Taiwan.
Tel: 886-935-605-578; Email: ccdivlaser1959@gmail.com

Received: Aug 31, 2023

Accepted: Sep 28, 2023

Published: Oct 05, 2023

Archived: www.jclinmedimages.org

Copyright: © Shin-Tsu C (2023).

Abstract

Elevated homocysteine level in serum or hyperhomocysteinemia is considered to be closely associated with neurological disorders such as stroke and cardiovascular diseases. However, to date, there have been limited studies on symptoms specifically associated with elevated homocysteine levels, resulting in infrequent diagnosis of hyperhomocysteinemia before patients experience a stroke or develop cardiovascular disease. We present a case of a lady with lower extremity pain and dizziness, who was ultimately diagnosed with increased homocysteine levels and mild hypoperfusion in multiple regions of the cerebral cortex. This highlights the significance of recognizing signs and symptoms associated with elevated homocysteine. Early detection of any skeletal/brain manifestations preceding major and severe symptoms allows for prompt treatment initiation, potentially preventing disease progression.

Introduction

Homocysteine (Hcy) is an amino acid derived from methionine with similar chemical structure to cysteine containing a sulfur component [1]. Methionine and Hcy serve as precursors for each other, and their synthesis serves as a mechanism for the detoxification of the other compound [2]. Various factors such as genetics, diet, lifestyle, and certain medications can contribute to elevated Hcy levels, known as Hyperhomocysteinemia (HHcy). Basically, the serum Hcy level is considered as normal ranging from 5 to 15 μ M, 16-50 μ M as mild, and up to 500 μ M as severe [3]. A latest article categorized normal range between 5.00 to 15.00 μ mol/L and moderate level as 16.00 to 30.00 μ mol/L [4].

HHcy is a disorder involving a wide variety of diseases, it arises when the metabolism of Hcy is disrupted due to deficiencies in B-vitamins, genetic defects, or other pathophysiological conditions [5,6]. HHcy have been convincingly linked to cardiovascular, cerebrovascular, neurodegenerative, and thromboembolic diseases, and also been found to have a close relationship with peripheral artery diseases [4,7-9].

Even though there are strong associations between Hcy and the diseases mentioned above, the symptoms HHcy may cause other than those known diseases remain unclear. Since there are currently few symptoms that can predict stroke or cardiovascular disease, we wonder if some of the signs and symptoms related with HHcy might help predict the possibility of those diseases. Furthermore, the relationship between cerebrovascu-

Citation: Hsuan-Hsuan H, Chia-Yuan G, Danielle Anne GT, Tsan-Yu H, Shin-Tsu C, et al. Early symptoms and signs of bony and brain lesions associated with hyperhomocysteinemia: Evidence with scintigraphic images of skeleton and brain. *Open J Clin Med Images*. 2023; 3(2): 1140.

lar diseases and HHcy has been discussed, and it is attempted to use a tool to detect the possibility of dysfunction of cerebral blood flow before the occurrence of the diseases. We herein present a case to show important information about symptoms and signs, as well as brain perfusion function.

Case presentation

A 45-year-old lady called at the emergency room of our hospital on January 30th, 2023 for an acute onset of severe right ankle pain while sleeping, with right hip and calf bursting pain, lower back soreness, and numbness on the medial side of the right foot. After initial survey, there was no significant abnormality in skeletal regions. Pain killer did not improve her discomfort, so she was transferred to outpatient clinic for help.

When the patient showed up at OPD on February 4th, 2023, she reported that she had been aching on her right calf and hip, and numbness on the medial side of the first toe of her right foot for many weeks. The feeling of pain and stiffness were strongest in the morning. She also had sudden dizziness which always occurred in a few seconds for 2-3 years, and the dizziness often occurred when sitting rather than standing, with transient stabbing pain and headache. Physical examination was check during visit and revealed local tenderness of the pelvis, right sacroiliac joint, and left flank region. Patrick's test showed slightly weaker on the left side. The Stork test and straight leg raising test were normal bilaterally. Hyperesthesia showed on the right side but do not affect functionally.

We arranged multiple tests including neurological testing, Whole Body Bone Scan (WBBS), and Single Photon Emission Computed Tomography (SPECT) of bone and brain, in order to obtain more information about her illness. The electro-physiological study of right lower extremity was interpreted as chronic right lower lumbosacral radiculopathy with neurogenic reinnervation signs. WBBS and ^{99m}Tc-methylene diphosphonate SPECT-CT (Figure 1) presented positive on the multiple areas with increased uptake on the right-sided L5 vertebral body and bilateral ischia. All blood test were within normal range except Hcy. The plasma Hcy level showed 21.70 $\mu\text{mol/L}$ (normal range between 5.00 to 15.00 $\mu\text{mol/L}$).

To explore the relationship between dizziness and brain blood flow, we arranged a cerebral perfusion scan of ^{99m}Tc-ethyl cystenat dimer-SPECT on March 25th, 2023, which showed inhomogeneous uptake of the cerebral cortex with mildly hypoperfusion over the bilateral sensorimotor cortices, and scale 1 relatively more prominent over the left side (Figure 2). From these images, we inferred that the patient might have Cerebral Small Vessel Disease (CSVD).

After being diagnosed HHcy on February 11th, 2023, we prescribed folic acid, vitamin B6 and B12 for her. Four months later, the Hcy level dropped to 8 $\mu\text{mol/L}$ checked on June 10th, 2023.

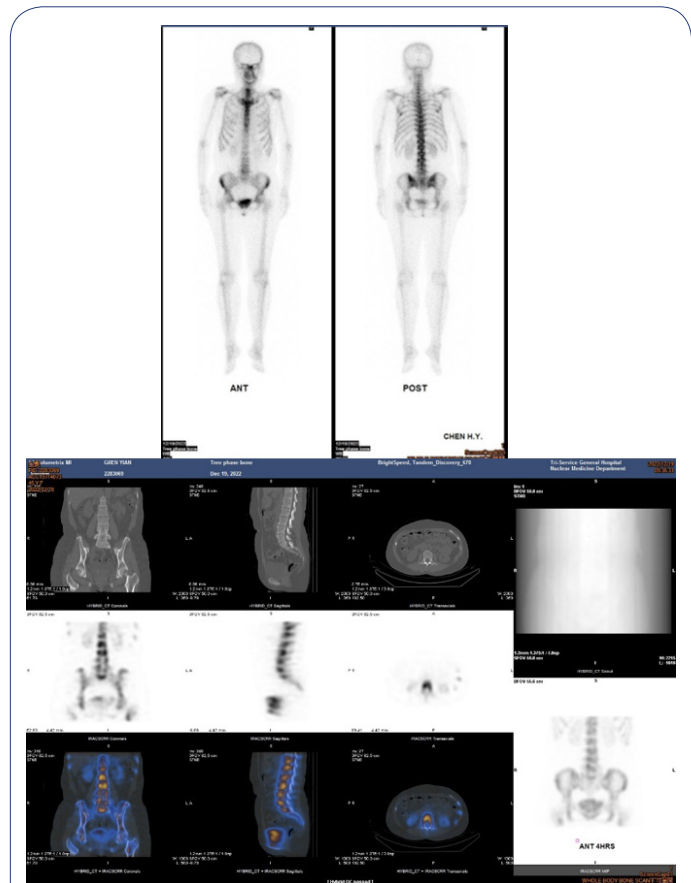


Figure 1: The WBBS (left panel) and SPECT-CT (right panel) show increased uptake over the right-sided L5 spine and bilateral ischia.

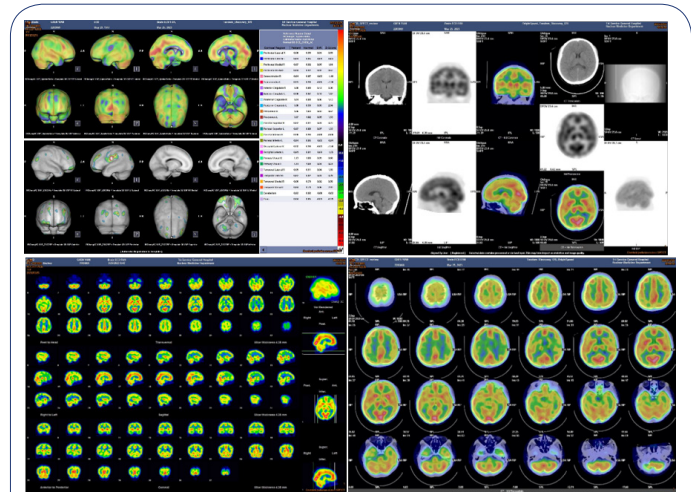


Figure 2: Findings of cerebral perfusion scan of SPECT. Inhomogeneous uptake of the cerebral cortex with mildly decreased uptake over the bilateral sensorimotor cortices, with scale 1 relatively more prominent over the left side (a-d).

*4-point scale for hypoperfusion [29]: 0: absent, 1: mild, 2: moderate, 3: severe.

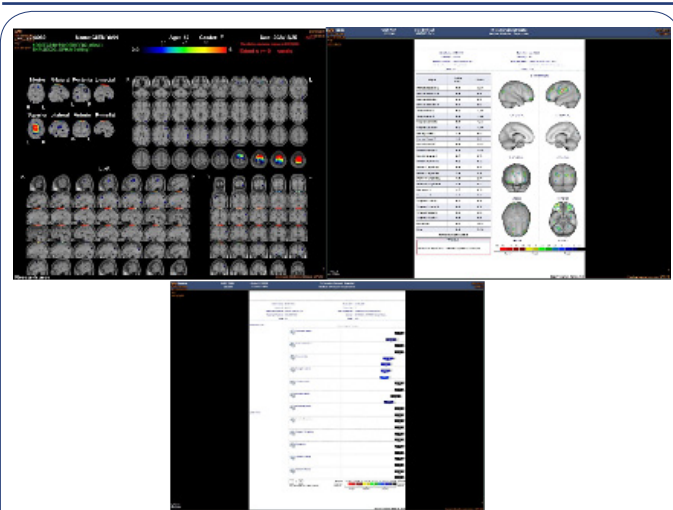


Figure 3: Findings of cerebral perfusion scan of SPECT. Inhomogeneous uptake of the cerebral cortex with mildly decreased uptake over the bilateral sensorimotor cortices, with scale 1 relatively more prominent over the left side (e-g).

*4-point scale for hypoperfusion [29]: 0: absent, 1: mild, 2: moderate, 3: severe.

Discussion

From this case, we have learned some symptoms that might be the signs of HHcy. Based on the results of imaging studies, we can list two main symptoms or signs: (1) lower limbs pain which exacerbated while sitting and could not be relieved by medicines immediately (2) dizziness occurred several times in one day in recent years which might be caused by hypoperfusion in the sensorimotor cortex of the left parietal lobe.

First of all, we should discuss the association between lower limbs pain and elevated Hcy levels. It has been determined that an increased level of blood Hcy is an autonomous risk factor for symptomatic lower extremity disease [10]. Since the patient experienced exacerbation while sitting and have local tenderness on the pelvis and right sacral-iliac joint, we should consider whether the problem came from radiculopathy. The problem of the lower limbs (from the waist down) might come from purely radiculopathy, yet we should not exclude the possibility that the symptoms might occur because of ischemia in the blood vessels supplying the nerves in the spine.

According to the images of the whole body bone scan and SPECT-CT, we can remark there is increased uptake at the right-sided L5 vertebra and bilateral ischia. As a result, there might be inflammation on the patient's L-spine. It is possible that the inflammation is simply the effect of degenerative joint disease in general, but we cannot exclude that these symptoms may be due to ischemia. It has been provided that elevated Hcy may raise the risk of Peripheral Artery Disease (PAD). Well controlling the level of Hcy could potentially reduce the incidence of PAD and help address the growing epidemic of PAD [9]. Furthermore, the increased total Hcy level has been categorized as a contributing factor to borderline Ankle-Brachial Index (ABI). A latest article confirmed that both borderline ABI and high total Hcy levels develop the uppermost threat of undesirable outcomes, emphasizing the mutually adjunctive significance of borderline ABI and total Hcy. More highlighting should be placed on recognizing the significance of borderline ABI in the patients with hypertension, particularly in persons with elevated Hcy levels [11]. Therefore, when discussing the etiology of lower limb symptoms in our lady, it is essential to take into account the association between PAD and Hcy levels. The pre-

cise and detailed relationship between these two factors will require further research to establish.

With respect to the correlation between dizziness, stroke, CSVD and elevated Hcy levels, it has been demonstrated that raised Hcy level is associated with higher threat of CSVD subtype of brain stroke [7,8,12]. CSVD is a prevalent cerebrovascular disorder characterized by pathological changes in the intracranial vasculature [13]. The CSVD is responsible for about 20% of all patients with strokes, including 25% of cerebral infarctions and 45% of cerebrovascular dementias [14-16]. While the clinical presentation and risk factors of CSVD are not yet fully understood, there has been a rise in the number of diagnoses [17]. The development of CSVD exhibits a dose-dependent correlation with serum total Hcy levels [18]. There is a significant higher Hcy levels observed in patients with CSVD or CSVD subtypes than healthy controls [19]. For every symptomatic stroke, there are about 10 silent brain changes, with CSVD being one of the common types of these subtle alterations [20]. The strong correlation between increased Hcy levels and balance impairments leading to dizziness can be attributed to its angiotoxic and neurotoxic effects [21]. Raised Hcy levels may enhance the risk of ischemic stroke by causing damage to the endothelial layer of vascular bed [22]. What's more, Hcy is deemed to be one of the markers of vascular inflammation/endothelial dysfunction [23]. Based on knowledge of the etiological foundations of age-related CSVD deepens, inflammaging is increasingly recognized as playing an essential role in its onset and progression [24]. As a result, dizziness can be something we should be concerned for the prevention of stroke. While the relationship between cerebrovascular diseases such as stroke and elevated Hcy are often discussed, it is uncommon to detect a reduction in brain blood flow prior to the occurrence of the diseases. As we have seen from the cerebral perfusion scan of SPECT of this lady, some small areas of the parietal cortex are hypoperfusion, which might be a sign of early-stage CSVD and the source of her dizziness.

HHcy has been known as an independent risk factor of cardiovascular events that is correlated with atherosclerotic vascular disorders and ischemic cardiac attacks. Plasma Hcy level increases the risk of cardiovascular diseases by damaging the vascular endothelium, so early detection of the Hcy level is important to prevent cardiovascular disease [22]. HHcy affects the occurrence and development of vascular diseases, even the mechanism has been concentrated in the roles of nitric oxide (NO) [25]. The potential mechanisms of reduction of nitric oxide bioavailability include the chronic inflammatory/prothrombotic conditions, the catalytic enzymatic inhibition by asymmetric dimethyl arginine, endoplasmic reticulum stress with eventual endothelial cell apoptosis, and the most important disrupting uncoupling of NO synthase activity and quenching of NO by oxidative stress [26].

Several potential pathways have been proposed regarding the truth of Hcy increases the risk of stroke and other vascular diseases. Increased levels of Hcy can contribute to the expected development of ischemic or hemorrhagic stroke through the following mechanisms: endothelial dysfunction, promotion of atherosclerosis, and induction of oxidative stress [26,27]. In light of the various symptoms described above, they are closely associated with the mechanisms. Therefore, if we can early detect patients with Hcy elevation by utilizing these symptoms and cerebral perfusion scan of SPECT, we can promptly control the concentration of Hcy in the blood, preventing the progres-

sion of these symptoms into irreversible damage.

To date, there is little article that emphasizes the symptoms and signs of HHcy. Yet, HHcy is known to be a risk of stroke and vascular disease. Moreover, these factors contributing to elevated Hcy are interconnected. For instance, females with PAD, either symptomatic or asymptomatic, are at increased risk for all-cause mortality, including cardiovascular mortality, like mortality from coronary artery disease [28,29]. If we can detect some aura earlier from the main and severe symptoms, the earlier the patients can receive treatments and prevent the progression of the disease.

Conclusion

Some of the symptoms we observed in this lady with multiple signs and symptoms and HHcy might help predict the likelihood of those diseases. In addition, we also found the cerebral perfusion in her cerebral cortex decreased slightly with the cerebral perfusion scan of SPECT. This case presentation may help people prevent and reduce the incidence of cerebrovascular and cardiovascular disease timely. Both skeletal bone scan with SPECT/CT and brain SPECT-CT provide the exact lesion(s) in skeleton and brain parenchyma, and play an important role in the authority of scintigraphic rehabilitation.

Declarations

Ethical approval and consent to participate: Not required for this case report.

Consent for publication: Not applicable.

Competing interests: The authors declare that the case report was written in the absence of any potential conflicts of interest.

Funding: No specific funding was received by this study.

Acknowledgments: The authors would like to express our heartfelt gratitude to Dr. Chia-Ying Lai for providing copies of the radiographs and imaging results.

References

1. Hermann A, Sitdikova G. Homocysteine: Biochemistry, molecular biology and role in disease. *Biomolecules*. 2021; 11.
2. Finkelstein JD, Martin JJ. Homocysteine. *The International Journal of Biochemistry & Cell Biology*. 2000; 32: 385-389.
3. Hasan T, Arora R, Bansal AK, Bhattacharya R, Sharma GS, et al. Disturbed homocysteine metabolism is associated with cancer. *Experimental & Molecular Medicine*. 2019; 51: 1-13.
4. Son P, Lewis L. Hyperhomocysteinemia. In *StatPearls*. 2023.
5. Liu TJ, Chen LC, Chu HY, Li TY, Lin CH, et al. Plasma homocysteine as a biomarker for screening lumbar disc herniation. *Asia Life Sciences*. 2014; 23: 633-639.
6. Miller JW. Homocysteine. In B. Caballero (Ed.), *Encyclopedia of Human Nutrition*. Academic Press. 213; 424-430.
7. Chang JY, Liu CC, Liu IT, Chang ST. Effects of intravascular laser irradiation of blood on cognitive function in a stroke survivor with hyperhomocysteinemia: Dual recuperations in thalamus and serum homocysteine. *Biomedical Journal of Scientific and Technical Research* 2019; 16:- 2109-11864-11868.
8. Li SA, Lin YP, Hsieh SP, Chang ST. Binary effects of intravascular laser irradiation of blood on motor recovery and homocysteine reduction in a case with ischemic hemiparesis: Portrayed with brain perfusion images. *BMC Neurology*. 2022; 22: 370.
9. Wang H, Wu P, Jiang D, Zhang H, Zhang J, et al. Relationship between serum homocysteine, fibrinogen, lipoprotein-a level, and peripheral arterial disease: A dose-response meta-analysis. *European Journal of Medical Research*. 2022; 27: 261.
10. Taylor LM, DeFrang RD, Harris EJ, Porter JM. The association of elevated plasma homocyst(e)ine with progression of symptomatic peripheral arterial disease. *J Vasc Surg*. 1991; 13: 128-136.
11. Li JP, Cao TY, Zha XY, Yu Y, Tan ZH, et al. Individual and joint effects of borderline ankle-brachial index and high plasma total homocysteine on all-cause death in hypertensive adults. *Journal of Geriatric Cardiology*. 2022; 19: 522-530.
12. Perini F, Galloni E, Bolgan I, Bader G, Ruffini R, et al. Elevated plasma homocysteine in acute stroke was not associated with severity and outcome: Stronger association with small artery disease. *Neurological Sciences*. 2005; 26: 310-318.
13. Zhong F, Zhuang L, Wang Y, Ma Y. Homocysteine levels and risk of essential hypertension: A meta-analysis of published epidemiological studies. *Clinical and Experimental Hypertension*. 2017; 39: 160-167.
14. Li Q, Yang Y, Reis C, Tao T, Li W, et al. Cerebral small vessel disease. *Cell Transplantation*. 2018; 27: 1711-1722.
15. Wardlaw JM, Smith C, Dichgans M. Small vessel disease: Mechanisms and clinical implications. *The Lancet Neurology*. 2019; 18: 684-696.
16. Chojdak-Lukasiewicz J, Dziadkowiak E, Zimny A, Paradowski B. Cerebral small vessel disease: A review. *Advances in Clinical and Experimental Medicine*. 2021; 30: 349-356.
17. Okroglic S, Widmann CN, Urbach H, Scheltens P, Heneka MT. Clinical symptoms and risk factors in cerebral microangiopathy patients. *PLoS One*. 2013; 8: e53455.
18. Nam KW, Kwon HM, Jeong HY, Park JH, Kwon H, et al. Serum homocysteine level is related to cerebral small vessel disease in a healthy population. *Neurology*. 2019; 92: e317-e325.
19. Piao X, Wu G, Yang P, Shen J, De A, et al. Association between Homocysteine and Cerebral Small Vessel Disease: A Meta-Analysis. *Journal of Stroke and Cerebrovascular Diseases*. 2018; 27: 2423-2430.
20. Smith EE, Saposnik G, Biessels GJ, Doubal FN, Fornage M, et al. Prevention of stroke in patients with silent cerebrovascular disease: a scientific statement for healthcare professionals from the American Heart Association/American Stroke Association. *Stroke*. 2017; 48: e44-e71.
21. Moretti R, Caruso P. The controversial role of homocysteine in neurology: from labs to clinical practice. *International Journal of Molecular Sciences*. 2019; 20.
22. Cao Y, Su N, Zhang D, Zhou L, Yao M, et al. Correlation between total homocysteine and cerebral small vessel disease: A Mendelian randomization study. *European Journal of Neurology*. 2021; 28: 1931-1938.
23. Low A, Mak E, Rowe JB, Markus HS, O'Brien JT. Inflammation and cerebral small vessel disease: A systematic review. *Ageing Research Reviews*. 2019; 53: 100916.
24. Li T, Huang Y, Cai W, Chen X, Men X, et al. Age-related cerebral small vessel disease and inflammaging. *Cell Death & Disease*. 2020; 11: 932.
25. Yan W, Cao Y, Zhen P, Ji D, Chai J, et al. Decreased autophagy of vascular smooth muscle cells was involved in hyperhomocysteinemia-induced vascular ageing. *Clinical and Experimental Phar-*

-
- macology and Physiology. 2021; 48: 524-533.
26. Lai WK, Kan MY. Homocysteine-induced endothelial dysfunction. *Annals of Nutrition and Metabolism*. 2015; 67: 1-12.
27. Lentz SR. Mechanisms of homocysteine-induced atherothrombosis. *Journal of Thrombosis and Haemostasis*. 2005; 3: 1646-1654.
28. Aronow WS. Peripheral arterial disease in women. *Maturitas*. 2009; 64: 204-211.
29. McMurtray AM, Chen AK, Shapira JS, Chow TW, Mishkin F, et al. Variations in regional SPECT hypoperfusion and clinical features in frontotemporal dementia. *Neurology*. 2006; 66: 517-522.